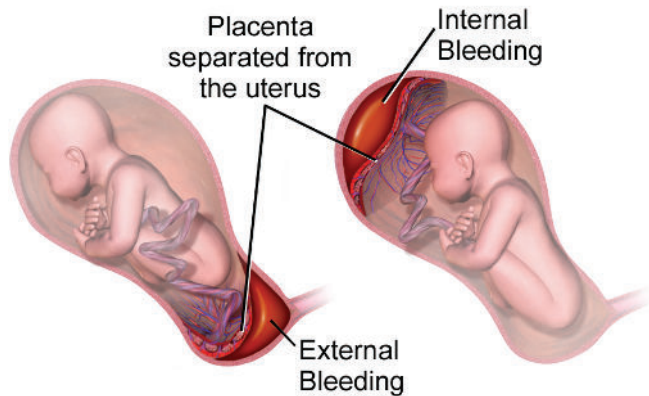


ABRUPTION VS PREVIA

Placental Abruption



Attribution: By BruceBlaus. When using this image in external sources it can be cited as: Blausen.com staff (2014). "Medical gallery of Blausen Medical 2014". WikiJournal of Medicine 1 (2). DOI:10.15347/wjm/2014.010. ISSN 2002-4436. - Own work, CC BY 3.0. <https://commons.wikimedia.org/w/index.php?curid=30462651>

• Description

- Detachment of the placenta from the uterine wall
- Disrupts flow of oxygen to fetus
- Emergency (will be delivered in operating room)

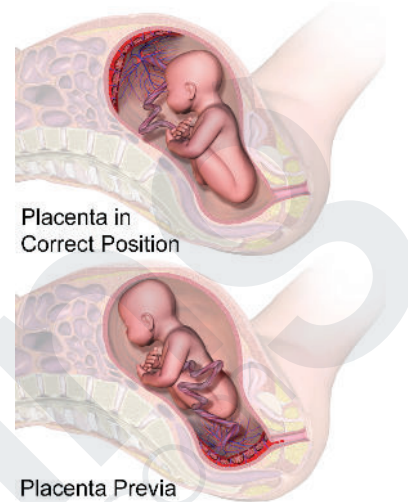
• Characteristics

- Rigid, board like abdomen in mother
- Abdominal pain by mother
- Possible external bleeding
- Late decelerations on monitor
- Fetal bradycardia

• Complications

- Disseminated intravascular coagulation
- Postpartum hemorrhage

Placenta Previa



Attribution: By BruceBlaus - Own work, CC BY-SA 4.0. <https://commons.wikimedia.org/w/index.php?curid=61131792>

• Description

- Attachment of the placenta over the cervix
- As cervix dilates, a portion of the uterus becomes detached from the uterine wall
- Delivery will be via cesarean section

• Characteristics

- Painless, bright red bleeding
- Bed rest may be indicated for this patient

• Complications

- Potential loss of perfusion to fetus due to partial/poor attachment of placenta to uterus