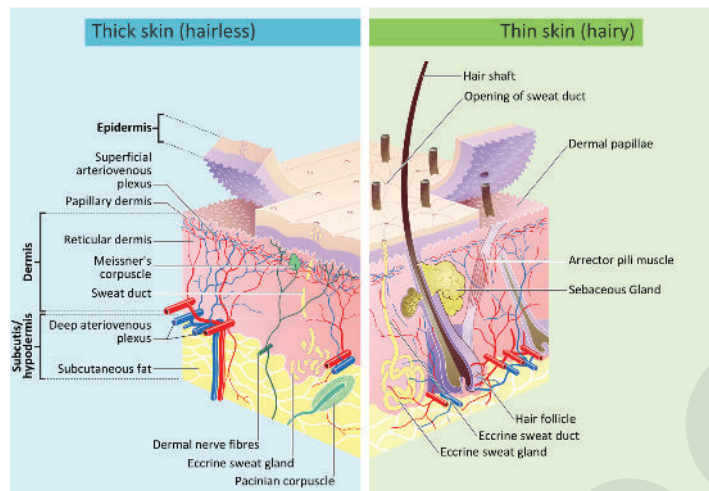


SKIN ANATOMY



Attribution: By Madhero88 and M.Komorniczak - https://en.wikipedia.org/wiki/File:Skin_layers.png,
CC BY-SA 3.0, <https://commons.wikimedia.org/w/index.php?curid=21986708>

Layers

Epidermis

- Epithelial tissue
- Made of keratinized stratified squamous

Dermis

- Connective tissue
- Vascular
- Nerve endings
- Hair follicles
- Oil glands

Subcutaneous

- Adipose tissue
- Areolar connective tissue
- Connects skin to muscle, cartilage & bone

Functions

Protection

- Against injury & infection
- Maintains fluid balance
- Against UV radiation

Other Functions

- Vitamin D production through sunlight absorption
- Excretion of wastes via the skin
- Forms identifying marks such as fingerprints or birthmarks

Sensory Detection

- Detects light touch (via Merkel's discs)
- Detects deep pressure
- Senses temperature
- Senses pain via nociceptors

Thermoregulation

- Assists with maintaining core temperature
- Adjusts for heat loss or gain through vasoconstriction or vasodilation
- Uses sweat mechanism to encourage heat loss (via evaporation)