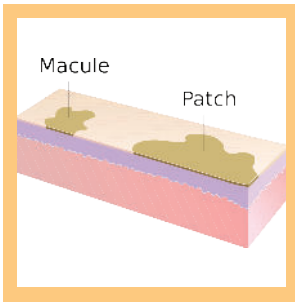


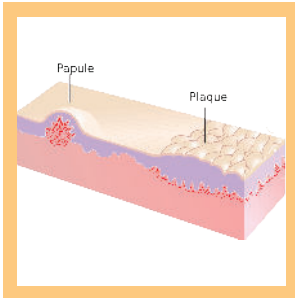
SKIN LESIONS



Macule and Patch

- A macule is a flat area of hyperpigmentation, usually < 10mm.
- A Patch is a larger macule (usually > 10mm).

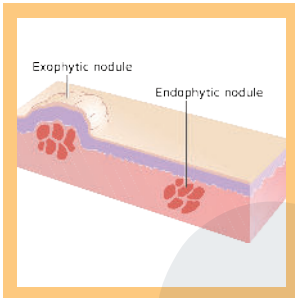
By Madhero88 - Own work, CC BY-SA 3.0, <https://commons.wikimedia.org/w/index.php?curid=14546457>



Papule and Plaque

- A papule is a well-defined raised area with no visible fluid, usually < 10 mm.
- A plaque is a large papule or group of them, usually > 10 mm, or a large raised plateau-like lesion

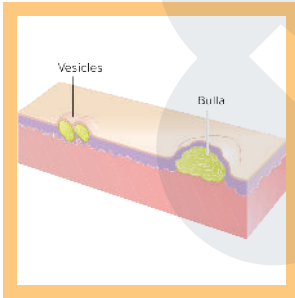
By Madhero88 - Own work, CC BY-SA 3.0, <https://commons.wikimedia.org/w/index.php?curid=14546485>



Nodules

- A nodule is similar to a papule - raised area with no fluid - but is much deeper in the dermis than a papule.

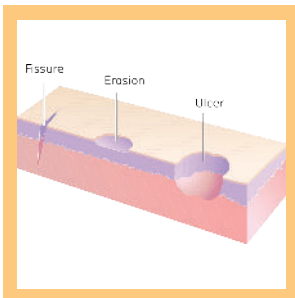
By Madhero88 - Own work, CC BY-SA 3.0, <https://commons.wikimedia.org/w/index.php?curid=14546471>



Vesicles and Bulla

- A vesicle is a small, well-defined raised area filled with fluid, usually <10mm.
- A Bulla is a large vesicle, usually >10mm.
- Both are also known as blisters.

By Madhero88 - Own work, CC BY-SA 3.0, <https://commons.wikimedia.org/w/index.php?curid=14546567>



Fissures, Erosions, and Ulcers

- A fissure is a crack in the skin that is usually narrow but deep.
- Erosions involve full loss of the epidermis in a defined area.
- Ulcers involve loss of the epidermis and some or all of the dermis.

By Madhero88 - Own work, CC BY-SA 3.0, <https://commons.wikimedia.org/w/index.php?curid=14546561>