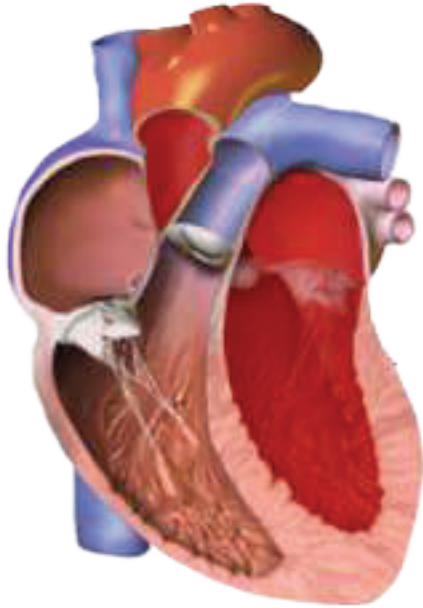
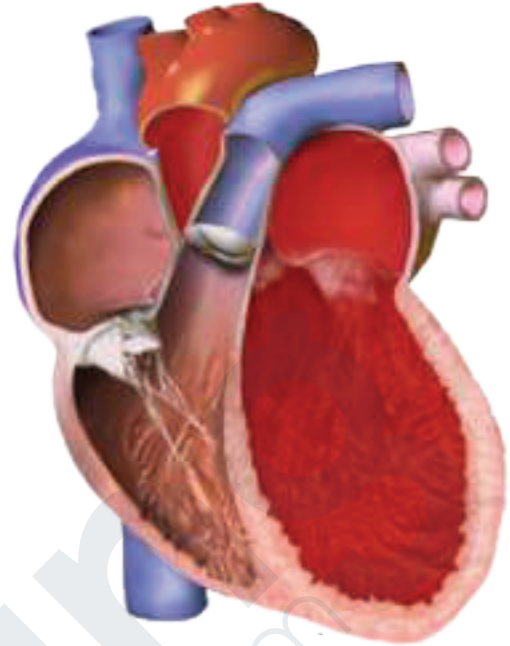


TYPES OF CARDIOMYOPATHY



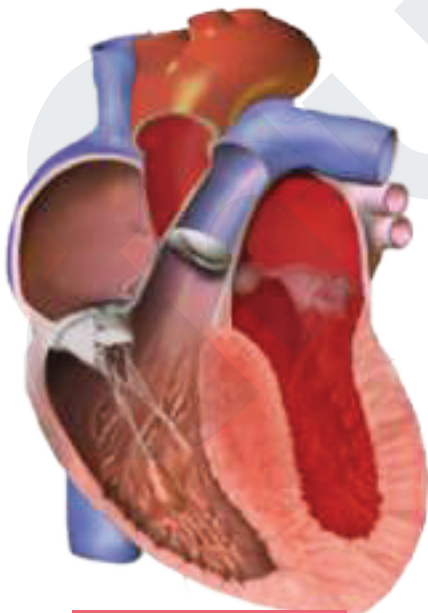
Normal

Normal Contraction
Normal Thickness
Normal Filling



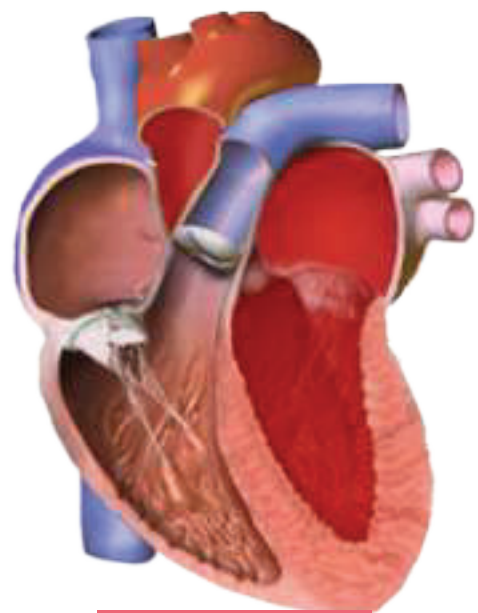
Dilated

Weak Contraction
Thinned Walls
• Normal Filling



Hypertrophic

Stiff Contraction
Thickened Walls
Restricted Filling



Restrictive

Normal Contraction
Normal Thickness
Restrictive Filling